


COLIC

SPECIFIC POINTS

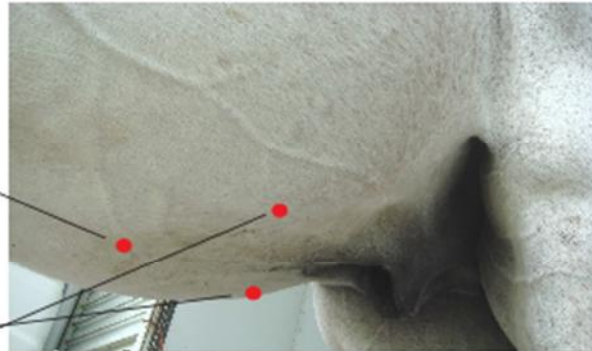
When confronted with a low grade colic in mares and fillies, which responds to photonic therapy and then reoccurs, always suspect ovarian cysts (refer to Cystic Ovaries or Ovarian Colic).

BL-20
Bladder 20 is one hand's breadth on either side of the spine in front of the last rib.



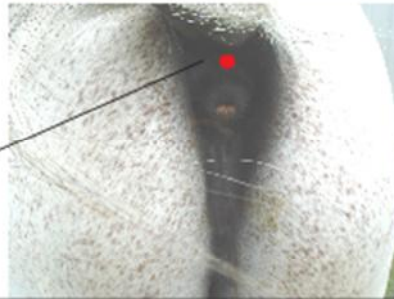
BL-21
Bladder 21 is one hand's breadth on either side of the spine behind the last rib.

CV-12
Conception Vessel 12 is on the mid-line of the ventral abdomen half way from the navel to the breast bone.



ST-25
Stomach 25 is two rib widths on either side of the navel.

GV-1
Governing Vessel 1 is in the depression between the top of the anus and the base of the tail.



Sample of some Colic Points from Horse Info Pack